

THE EFFECT OF OVARECTOMY ON THYROID C CELLS OF ADULT RATS

Branko Filipović, Branka Šošić-Jurjević, Milica Manojlović-Stojanoski,
Nataša Nestorović, Verica Milošević, Milka Sekulić

Institute for Biological Research »Siniša Stankovićá, Belgrade, Yugoslavia

Summary: The structure and function of C cells of adult female rats after ovariectomy (Ovx) were investigated. Intact control and Ovx rats were i.p. treated with sterile olive oil for 4 weeks. Peroxidase-antiperoxidase (PAP) immunohistochemical procedure was applied to localize calcitonin (CT) in thyroid C cells while its serum content was determined by RIA method. Morphometric analyses of the C cells volume, that of their nuclei and relative volume density included stereological method with the multipurpose test system M₄₂. Also, the average number of C cells number *per* mm² was calculated. Ovx led to a significant increase in body weight (21%; $p < 0.005$). At the same time the C cells of Ovx rats had a significantly decreased cell volume (13%; $p < 0.005$) and their number *per* mm² was increased by 59% ($p < 0.001$) in comparison with the controls. Ovx resulted in reduction of serum CT level by 45% comparing to the corresponding controls. Based on these data it can be concluded that Ovx inhibits both the structure and function of the C cells.

Key words: female rats, thyroid, C cells, ovariectomy, immunohistochemistry, morphometry.

Introduction

Estradiol is widely applied for the prevention of health problems in menopausal and postmenopausal women, due to ovarian hormone deficiency (1). Menopause, as a natural event in women, and oophorectomy represents one of risk factors for the development of osteoporosis and reduced serum levels of estradiol, testosterone and dehydroepiandrosterone were found in both events (2). Because ovariectomy (Ovx) is known to induce osteopenia in rats, Ovx rats have been often used as an animal model for postmenopausal osteoporosis (3, 4). At present, it is possible to prevent menopause-related accelerated bone loss with a variety of agents such as estrogen, CT and some forms of biphosphonate (5).

Estrogen deficiency plays a significant role in the regulation of calcitonin (CT) production and secretion. Numerous authors demonstrated decreased concentrations of circulating CT after Ovx in the rats and women in early menopause (6–9). Isaia et al. (10) observed no response of CT secretion to calcium infusions to premenopausal women one year after oophorectomy.

However, this response to calcium infusions was significant one year after estrogen-progestogen treatment. On the other hand, Tiegs et al. (11) showed that basal CT concentrations in the blood sera were significantly higher in postmenopausal women with osteoporosis than in healthy controls and concluded that postmenopausal osteoporosis is not associated with CT deficiency.

The C cells are target organs for estrogen as suggested by Naveh-Many et al. (12) and 17 β estradiol, given to ovariectomized rats, led to a 4-fold increase in CT mRNA level. This could be interpreted as a direct effect of estrogen deficiency on CT secretion. However, Frolich et al. (13) detected no estrogen receptors in normal and malignant C cells. The changes of C cells after Ovx could be also the result of an indirect effect. The presence of CT and CT like peptides in some regions of human and rat brain including the hypothalamus and the anterior pituitary gland, suggest a physiological role for CT-like products in these tissues (14, 15). Li and Shah (16) showed that Ovx induced a large increase in pituitary CT secretion. Shah et al. (17) observed a dramatic increase of serum prolactin (PRL) level in Ovx rats after i.v. CT administration and a significant increase in PRL release from cultured anterior pituitary cells.

CT secretion may also be regulated by thyroid hormones and administration of T₄ was shown to lead

Address for correspondence

Branko Filipović
Institute for Biological Research »Siniša Stankovićá
29 Novembar 142
11060 Belgrade, Yugoslavia
E-mail: brankof@ibiss.bg.ac.yu

to a decrease in the basal level of plasma CT in Ovx rats (18). Besides, Body et al. (19) observed a decreased plasma level of CT in hypothyroid patients.

The volume density of C cells in castrated pigs was significantly increased as compared to the corresponding controls and at the same time a decrease in the number of C cells accompanied by the reduction of the volume density in estradiol- and progesterone-treated pigs was observed (20). However, Sakai et al. (9) reported that estrogen deficiency provoked by Ovx led to a decrease in the number of rat thyroid C cells and the number of secretory granules in these cells, as well as in the area occupied by the Golgi complex.

All these data prompted us to examine immunocytochemical, morphometric and biochemical changes of thyroid C cell under conditions of sex steroid deficiency provoked by Ovx in order to estimate whether the structure and function of these cells is disturbed.

Material and Methods

Animals

Female Wistar 3-month-old rats, maintained at a 12/12 light-dark cycle and 22 °C with free access to food and water, were used. The animals, bred at the Institute for Biological Research, Belgrade, were humanly treated according to the regulations of this institution. They were ovariectomized by abdominal incision under light nembutal anesthesia (Ovx). One month after the gonadectomy the rats were i.p. injected with sterile olive oil once a day except on Sunday for 4 weeks. Intact controls were treated with olive oil by the same schedule. All rats were killed two months upon the surgery under ether anesthesia 24 h after the last injection. Blood was collected from individual animals and sera prepared. The sera were stored at -70 °C until assayed for CT level.

Immunohistochemical studies

The thyroid glands together with a portion of the adjoining trachea and esophagus were immediately excised. The tissue samples were fixed in Bouin's solution at room temperature for 48 h, embedded in paraffin and serially sectioned at 5 µm on gelatine-coated slides. For localization of CT in the C cells, the peroxidase-antiperoxidase (PAP) method was applied (21).

Morphometry

The sections of thyroid glands with specifically labelled C cells were stereologically analyzed by simple point counting (22). The mean volume of the cytoplasm and the nuclei of the C cells and numerical density of nuclear profiles of these cells were determined with the multipurpose test system M_{42} (22) using 50 test areas and 1000× magnification. Numerical density of the C cells nuclei/mm³ (and thus of the cells) was determined according to the formula of Weibel and Gomez (22). The shape coefficient β was assumed to be 1.382 for the C cell nuclei (22). Subsequently, relative volume densities of CT-positive cells expressed as a percentage of total thyroid gland tissue were calculated.

Also, immunoreactive C cells were counted in all sections and the average number of C cells/mm² was calculated.

Hormone assay

CT content in the sera was determined by a CT RIA kit, using goat antiserum to synthetic human CT and synthetic human CT for standard and tracer (Diagnostic System Laboratories, Webster, USA). The intra- and interassay coefficients of variation for serum CT were 7.1% and 10.6%, respectively, and the reference interval 0–42 pmol/L.

Statistical analysis

All morphometric and biochemical data for each rat were averaged *per* group and SEM was calculated. The significance of the differences was evaluated by Student's t-test.

Results

Effect of Ovx on body weight

The data on body-weight before and after Ovx are summarized in Table I. As seen, Ovx led to a significant increase in body weight (21%; $p < 0.005$) in comparison with the controls.

Morphometric findings

In the Ovx rats, significantly decreased cell volumes (13%; $p < 0.005$) and increased C cell number per mm² (59%; $p < 0.001$) (Figure 1a,d) in comparison with controls were found. No statistically significant differences of nuclear volume and relative volume densities of the C cells of Ovx rats in comparison with the corresponding controls were observed (Figure 1b, c).

Immunohistochemical findings

Control thyroid C cells immunostained positively for CT had granular DAB deposits in the cytoplasm. Positively stained C cells were brown in color while counterstained nuclei were blue. CT reactive cells were widely scattered in the interfollicular and parafollicular areas in clusters or singly. They were oval or polygonal in shape and never faced the follicular lumen (Figure 2). The C cells of Ovx rats were numerous, smaller and the cytoplasm contained darker granular immunoreactive products when compared to C cells of the controls (Figure 3).

Serum parameter

Ovx resulted in a reduction of serum CT (by 45%) in comparison with the corresponding control values (Figure 4).

Table I Effects of Ovx on body weight (b.w.) of adults female rats. The results are means ± SEM (n=18)

b.w. Before Ovx (g)	b.w. After Ovx (g)
232 ± 11	281 ± 8 (21%) **
** P<0.005	

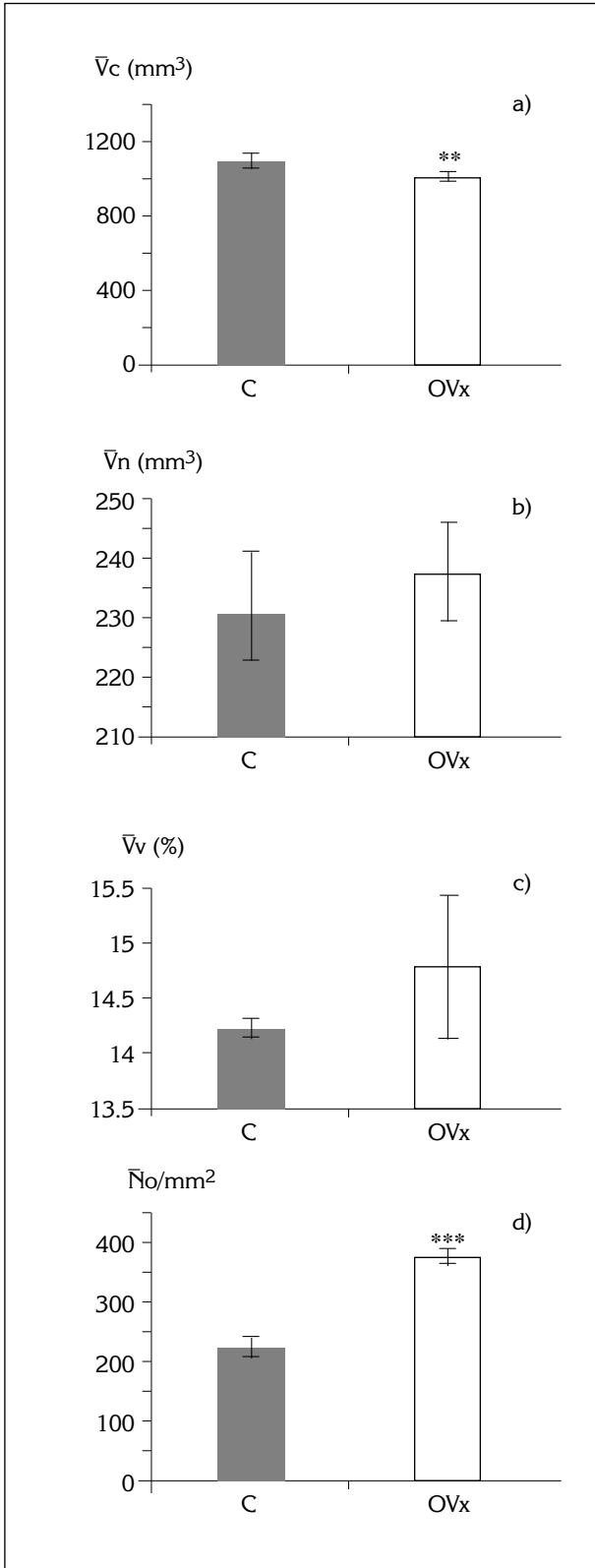


Figure 1. a) Cellular (\bar{V}_c) volume (μm^3) of the immunoreactive C cells. b) Nuclear (\bar{V}_n) volume (μm^3) of C cells. c) Relative volume density (\bar{V}_v) of C cells expressed in % of total gland tissue. d) Mean number (\bar{N}_o) per mm^2 of C cells. C control, Ov x ovariectomized rats. All values are the means SEM, ** $p < 0.005$, *** $p < 0.001$.

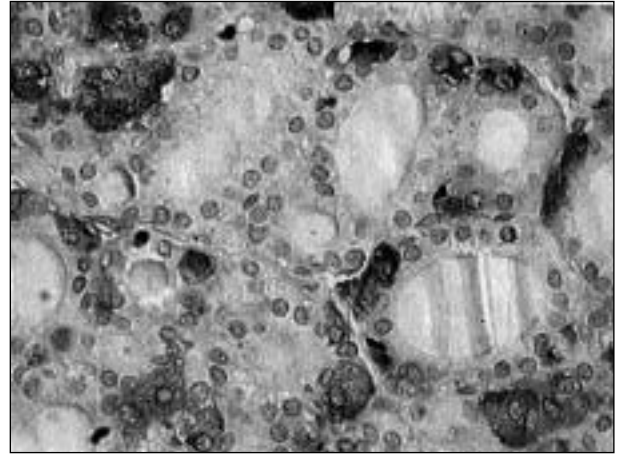


Figure 2. Thyroid C cells of a control female rat. Immunoperoxidase staining specific for calcitonin. (Objective magnification 40x).

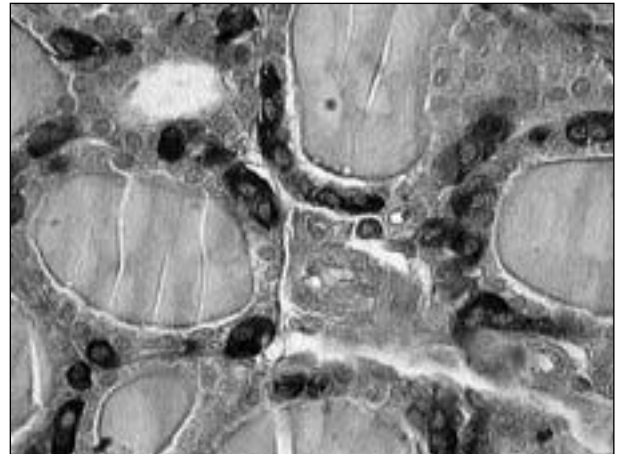


Figure 3. A marked increase in immunoreactivity for calcitonin in the C cells of Ov x female rats. Immunoperoxidase staining specific for calcitonin. (Objective magnification 40x).

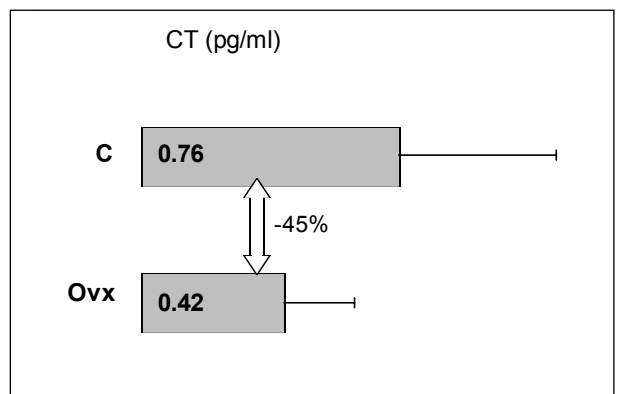


Figure 4. Changes in serum level of calcitonin (CT) in control (C) and ovariectomized (Ov x) rats.

Discussion

Since the role of gonadal steroids and their interrelation with calcium-regulating hormones is still unclear, numerous studies were devoted to investigations on the effect of gonadectomy on the CT, especially in human medicine after bilateral oophorectomy. The answer to the question, whether estrogen deficiency plays a significant role in the regulation of CT production and secretion may be of a great importance in explaining the pathogenesis of hypoestrogenic osteoporosis.

Ovx rats have been frequently used as a model for postmenopausal osteoporosis and replacement therapy with estrogen or its analogs to prevent bone loss. Ovx induced in rats a strong increase in bone resorption as a result of increased number of osteoclasts along the trabecular bone surface and plasma osteocalcin concentration. Also, Ovx was shown to cause a marked reduction of serum estradiol, serum alkaline phosphatase, a decrease in bone density, serum CT and Ca levels (3, 4, 23, 24). On the other hand, Garner et al. (25) found that the removal of the ovaries from the lactating rats does not significantly affect lactation and does not lead to the loss of bone mass. Since the level of plasma CT is influenced by gonadal steroid hormones, the aim of the present study was to examine how deficiency of sex steroids after Ovx affects the structure and function thyroid C cells. Our results showed that body weight gain of Ovx rats was significantly higher comparing to the controls, while CT secretion was diminished. This is in accordance with the data of several authors (26, 27). Basal serum CT levels were markedly lower in Ovx than in control rats, and estradiol alone or in combination with progesterone prevented this decrease as shown by Grauer et al. (8), Lu et al. (18) and Tsai et al. (28). These authors also determined the CT content in thyroid glands of Ovx animals and observed no significant differences between control, Ovx and estradiol-supplemented rats. This finding, however, does not exclude a direct effect of estradiol deficiency on CT gene transcription but it is unlikely that decreased CT gene transcription accounts for a decreased CT secretion and the mechanism of a possible direct effect of estradiol deficiency on CT secretion is still a matter of debate. It has been confirmed that the C-cells are targets for estrogen, and Silver and Naveh-Many (29) suggested that CT-gene is regulated by vitamin D and estrogens. Taggart et al. (6) reported that estradiol deficiency, such as that in menopausal women, leads to diminished basal serum CT levels. One year after oophorectomy in premenopausal women no response of CT secretion to Ca infusions was observed (10). This response was evident only in oophorectomic women after a year of estrogen-progestogen therapy (10). In other reports CT levels measured in immunoextracted plasma of postmenopausal women were not significantly lower than those of age-matched controls (11).

Similar to estrogen, androgen deficiency has also been shown to play an influential role in the pathogenesis of osteoporosis in hypogonadal subjects but the

exact mechanism of its action is still unclear. Foresta et al. (30) suggested that androgen influences bone metabolism by regulating CT secretion. In the pigs castrated on the first postnatal day, serum estradiol level was significantly decreased during the first two weeks of age and after that, approached control levels (31). Our previous results showed that neonatal castration of 1-day-old piglets influenced thyroid C cells morphology. Volume densities of C cells were significantly increased, while the number of these cells *per* unit area was decreased. Also, a markedly developed lamellar structure of GER with numerous attached ribosomes and many mitochondria in the cytoplasm suggested the stimulation of specific protein synthesis (20).

Besides the thyroid gland, some brain regions including the hypothalamus and anterior pituitary gland contain CT and CT-like peptides, suggesting a physiological role of CT-like products in these tissues (14, 15). It is possible that CT plays a neuroendocrine role and thus the changes of C cells under conditions of sex steroid deficiency provoked by Ovx could be the result of an indirect effect on C cells. According to Li and Shah (16), Ovx induced a large increase in CT-like immunoreactive peptide secretion synthesized by the anterior pituitary. CT given *i.v.* to Ovx rats acted stimulating PRL release from primary anterior pituitary cells and leading to a dramatic increase in serum PRL level, as shown by Shah et al. (17). The results of Lu et al. (18) suggest a possibility of paracrine interaction between the function of C cells and thyroid follicular cells, because the administration of T₄ decreased the basal levels of plasma CT in Ovx rats.

Our experimental model of the Ovx rat has been used to study the relationship between estradiol deficiency and thyroid C cells structure and function. A decrease in the volume of C cells and the level of serum CT concentration by 45% in Ovx rats as compared to the controls observed in the present study clearly suggests certain disturbances in the structure and an inhibition of the function of these cells. On the other hand, the number of these cells in Ovx rats was increased in comparison with the controls. Sakai et al. (9) recently demonstrated that the lack of estrogen provoked by Ovx decreased the number of C cells, as well as the number of secretory granules within these cells and in the area occupied by the Golgi complex what is the sign of reduced synthesis and release of CT.

Based on the results obtained throughout the present study, it can be concluded that deficiency of sex steroids provoked by Ovx results in inhibition of CT synthesis and secretion by thyroid C cells. Whether this effect of estrogen deficiency is direct or indirect one and what is the exact mechanism involved in the above processes remains to be elucidated.

Acknowledgements. The authors are very thankful to Dr Jelena Joksimović, for her interest in this work and her benevolent criticism. This work was supported by the Ministry for Science, Technology and Development of Serbia, Grant #1710.

UTICAJ OVARIJEKTOMIJE NA C ĆELIJE ŠTITASTE ŽLEZDE ADULTNIH PACOVA

Branko Filipović, Branka Šošić-Jurjević, Milica Manojlović-Stojanoski,
Nataša Nestorović, Verica Milošević, Milka Sekulić

Institut za biološka istraživanja »Siniša Stanković«, Beograd, Jugoslavija

Kratak sadržaj: U ovom radu ispitivana je struktura i funkcija C ćelija adultnih ženki pacova posle ovarijektomije (Ovx). Intaktne kontrolne i Ovx životinje su tretirane *i.p.* sterilnim maslinovim uljem u trajanju od četiri nedelje. Za lokalizaciju kalcitonina (CT) u C ćelijama štitaste žlezde korišćena je imunohistohemijska metoda peroksidaze-antiperoksidaze (PAP). Nivo CT-a u serumu određen je RIA metodom. Morfometrijska ispitivanja volumena C ćelija, njihovih jedara i relativne volumenske gustine ćelija vršena su višenamenskim testnim sistemom M₄₂. Takođe je izračunat broj C ćelija po mm². Statistička obrada podataka vršena je Studentovim t-testom. Posle Ovx-a telesna masa životinja značajno je povećana za 21% ($p < 0.005$). Volumen C ćelija Ovx pacova značajno je smanjen za 13% ($p < 0.005$), njihov broj po mm² povećan za 59% ($p < 0.001$), a nivo CT-a u serumu smanjen za 45% u poređenju sa intaktnom kontrolom. Na osnovu dobijenih rezultata možemo zaključiti da Ovx deluje inhibitory na strukturu i funkciju C ćelija štitaste žlezde kod pacova.

KLjučne reči: ženke pacova, štitasta žlezda, C ćelije, ovarijektomija, imunohistohemija, morfometrija.

References

1. Prince RL. Counterpoint: Estrogen effects on calcitropic hormones and calcium homeostasis. *Endocr Rev* 1994; 15: 301 9.
2. Otha H, Masuzawa T, Ikeda T, Suda Y, Makita K, Nozawa S. Which is more osteoporosis-inducing, menopause or oophorectomy? *Bone Min* 1992; 19: 273 85.
3. Kalu D, Hardin R, Cockerham R. Evaluation of the pathogenesis of skeletal change in ovariectomized rats. *Endocrinology* 1984; 115: 507 12.
4. Wronski TJ, Lowry PL, Walsh CC, Ignaszewski LA. Skeletal alterations in ovariectomized rats. *Calc Tissue Int* 1985; 37: 324 8.
5. Shen V, Demoster DW, Mellish RWE, Birchman R, Horbert W, Lindsay R. Effects of combined and separate intermittent administration of low-dose human parathyroid hormone fragment (1-34) and 17 β -estradiol on bone histomorphometry in ovariectomized rats with established osteopenia. *Calcif Tissue Int* 1992; 50: 214 20.
6. Taggart HM, Chesnut CH, Ivery JL, Baylink DJ, Sisom K, Huber MB, et al. Deficient calcitonin response to calcium stimulation in postmenopausal osteoporosis. *Lancet* 1982; i: 475 8.
7. Yamazaki I, Kinoshita M. Calcitonin secreting property of ipriflavone in the presence of estrogen. *Life Sci* 1986; 38: 1535 41.
8. Grauer A, Klein P, Naveh-Many T, Silver J, Ziegler R, Raue F. Diminished calcitonin secretion after ovariectomy without apparent reduction in calcitonin content in the rat. *Horm Metab Res* 1993; 25: 389 90.
9. Sakai K, Yamada S, Yamada K. Effect of ovariectomy on parafollicular cells in the rat. *Okajimas Folia Anat Jpn* 2000; 76: 311 9.
10. Isaia GC, Mussetta M, Massobrio M, Sciolla A, Gallio M, Molinatti GM. Influence of estrogens on calcitonin secretion. *J Endocrinol Invest* 1992; 15: 59 62.
11. Tiegs RD, Body JJ, Wahner HW, Barta J, Riggs BL, Heath H. Calcitonin secretion in postmenopausal osteoporosis. *N Engl J Med* 1985; 312: 1097 100.
12. Naveh-Many T, Almogi G, Livni N, Silver J. Estrogen receptors and biologic responses in rat parathyroid tissue and C cells. *J Clin Invest* 1992; 90: 2434 8.
13. Frolich A, Christensen L, Andersen J. Estrogen receptors appear undetectable in the C-cells of the human thyroid gland. *Bone* 1990; 11: 393 6.
14. Fisher LA, Kikkawa DO, Rivier JE, Amara SG, Evans RM, Rosenfeld MG, et al. Stimulation of noradrenergic sympathetic outflow by calcitonin gene-related peptide. *Nature* 1983; 305: 534 6.
15. Sexton PM, Hilton JM. Biologically active salmon calcitonin-like peptide is present in rat brain. *Brain Res* 1992; 596: 279 84.
16. Li Z, Shah GV. Estrogen attenuates expression of calcitonin-like immunoreactivity in the anterior pituitary gland. *Endocr J* 1995; 3: 452 9.
17. Shah GV, Pedchenko V, Stanley S, Li Z, Samson WK. Calcitonin is a physiological inhibitor of prolactin secretion in ovariectomized female rats. *Endocrinology* 1996; 137: 1814 22.
18. Lu SS, Tsai SC, Wang SW, Tsai CL, Lau CP, Shih HC, et al. Effect of ovarian steroid hormones and thyroxine on calcitonin secretion in pregnant rats. *Am J Physiol* 1988; 37: E246 52.

19. Body JJ, Demeester-Mirkine N, Borkowski A, Suciú S, Corvilain J. Calcitonin deficiency in primary hypothyroidism. *J Clin Endocrinol Metab* 1986; 62: 700-3.
20. Sekulić M, Lovren M. Thyroid parafollicular cells in intact pigs, neonatally treated with gonadal steroids or castrated. *Acta Vet* 1995; 45: 203-14.
21. Sekulić M, Lovren M, Milošević V, Mićić M, Balint-Perić LJ. Thyroid C cells of middle-aged rats treated with estradiol or calcium. *Histochem Cell Biol* 1998; 109: 257-62.
22. Wiebel ER. Stereological methods. Partical methods for biological morphometry. Academic Press, London 1979; 1: pp 1-415.
23. Kalu DN, Liu CC, Salerno E, Hollis B, Echon R, Ray M. Skeletal response of ovariectomized rats to low and high doses of 17β -estradiol. *Bone and Mineral* 1991; 14: 175-87.
24. Gaumet N, Seibel MJ, Coxam V, Davicco MJ, Lebecque P, Barlet JP. Influence of ovariectomy and estradiol treatment on calcium homeostasis during aging in rats. *Arch Physiol Biochem* 1997; 105: 435-44.
25. Garner SC, John JB, Anderson MHM, Parikh I. Estrogens reduce bone loss in the ovariectomized, lactating rat model. *Bone and Mineral* 1991; 15: 19-31.
26. Cressent M, Bouizar Z, Pidoux E, Moukhtar MS, Milhaud G. Effect of ovariectomy on circulating calcitonin levels in the rat. *C R Seances Acad Sci D* 1979; 289: 501-4.
27. Kalu D, Hardin R. Evaluation of the role of calcitonin deficiency in ovariectomy-induced osteopenia. *Life Sci* 1984; 34: 2393-8.
28. Tsai CL, Wong TY, Lau CP, Tsai SC, Wang PS. Different effects of estradiol and progesterone on the secretion of calcitonin in ovariectomized rats. *Chin J Physiol* 1992; 35: 1-7.
29. Silver J, Naveh-Many T. Calcitonin gene regulation in vivo. *Horm Metab Res* 1993; 25: 470-2.
30. Foresta C, Zanatta GP, Busnardo B, Scanelli G, Scandellari C. Testosterone and calcitonin plasma levels in hypogonadal osteoporotic young men. *J Endocrinol Invest* 1985; 8: 377-9.
31. Pantić V, Gledić D, Milovanović O. Testicular structure and serum concentration of gonadal steroids in male pigs neonatally castrated or treated with estradiol and progesterone. *Bull Acad Serbe Sci et Arts Classe Sci Mathemat et Nat Sci T LXXXVI* 1984; 25: 57-72.