

EFFECT OF CALCIUM ON STRUCTURAL AND MORPHOMETRIC FEATURES OF THYROID GLAND TISSUE IN MIDDLE-AGED RAT FEMALES

Branka Šošić-Jurjević, Branko Filipović, Nataša Nestorović, Mirjana Louren, Milka Sekulić

Institute for Biological Research »Siniša Stanković«, Belgrade, Yugoslavia

Summary: The subject of these studies was the thyroid gland tissue of middle-aged (14-month-old) female rats chronically treated with calcium glucoheptonate. The peripheral and central zone of the thyroids were stereologically analysed and the following morphometric parameters determined: the height and volumetric density of follicular epithelium, colloid, interstitium and follicles and index of activation rate. The height of follicular epithelium, its volume density and index of activation rate were significantly reduced (by 8%, $p < 0.05$, 18%, $p < 0.025$ and 34%, $p < 0.01$, respectively) as compared to the controls. However, the volumetric density of colloid and interstitium were increased (by 10% and 14% respectively). These morphometric results indicate that Ca treatment expressed an inhibitory effect on thyroid follicular cells structure in middle-aged female rats.

Key words: middle-aged female rats, thyroid, follicular cells, calcium, morphometry.

Introduction

Menopause in women transiently increases the declining of the bone mass at most or all skeletal sites, thus representing the major risk in developing osteoporosis. Randomized clinical trials have demonstrated that adequate calcium intake from diet or supplementation increases the bone mineral density and reduces the bone loss (1).

Although this therapy has medical benefit on bone tissue, calcium as a key cell mediator may affect almost all other, »non-therapy targetted« tissues. One of these is endocrine thyroid follicular tissue, especially since it is colocalized with the C cells the function of which is directly dependent on blood Ca level. In response to elevated blood Ca concentration, C cells secrete calcitonin and serotonin, the latter representing a neurohormone that is possibly a paracrine stimulating factor of follicular cells activity (2–4).

According to the available data, Ca can affect thyroid follicular cells directly, adenyl cyclase system being a possible molecular target of its action. Gaberscek et al. (5) reported that extracellular Ca even at high concentrations did not affect morphology of follicular FRTL-5 cell culture, but given together with TSH, Ca diminished thyrotropin stimulatory effect, probably by inhibiting adenyl cyclase. Vanvooren et al. (6) observed the presence of distinct adenyl cyclase (AC) families in human and dog thyroids, which respond to different agents. They showed that one of the AC subtypes (AC VI) is negatively modulated by Ca.

Indirectly, through its inhibitory influence on the pituitary TSH cells, Ca can affect the thyroid follicular cells, as well. Gillet et al. (7) and Bergenfelz et al. (8) reported decreased serum TSH levels in patients after different types of Ca treatment. Sekulić et al. (9) suggested that chronic Ca treatment reduced the synthetic capacity of TSH pituitary cells in middle-aged female rats.

The aim of the present work was to study the effect of Ca supplementation therapy on structural and morphological features of the thyroid gland tissue in middle-aged female rats. Some of the findings described herein have been previously presented in an abstract form (10).

Address for correspondence

Branka Šošić-Jurjević
Institute for Biological Research »Siniša Stankovićá
29. Novembra 142
11060 Belgrade, Yugoslavia
E-mail: brankica@ibiss.bg.ac.yu

Material and methods

Wistar 14-month-old female rats were housed in a room with controlled temperature (22 °C) and humidity (60%) under 12 h illumination cycle. They were fed with laboratory chow and water *ad libitum*. The treatment group was given *i.m.* 28.55 mg kg⁻¹ b.w. Ca-glucoheptonate per day for two weeks every day except on Sundays. The animals were sacrificed 24 h after the last injection, the thyroids were immediately excised, fixed in Bouin's solution and embedded in paraffin. Serial sections of whole gland were stereologically analyzed. Morphometric parameters volume densities of follicular cells (Vve), interstitium (Vvi), colloid (Vvc) and follicles (Vvf), expressed *per* mm³, as well as index of activation rate ($ia = Vve/Vvc$), were calculated by the Weibel test system (M42) (11) on a Zeiss light microscope at 40× magnification. The height of follicular cells (τ) was determined according to Bogataj et al. (12). Follicles in contact with the surface of the thyroid lobes and isthmic follicles are referred to as peripheral ones while the other follicles are referred to as central ones (13, 14). The results were statistically evaluated by Student's t-test.

Results

The thyroid gland tissue consists of central and peripheral follicles (13 15) and the results obtained after structural and stereological analyses of these zones are reported separately.

Central Thyroid Zone. Central thyroid zone of the control rats is characterized by a small diameter follicles composed of highly prismatic epithelium and a small portion of light coloured colloid (Figure 1). However, microfollicles of Ca-treated animals had flattened, light epithelium. Occasional enlarged macrofollicles with denser colloid were noticeable in this area (Figure 2).

This zone was much more affected by Ca treatment than the peripheral one and the following morphometric parameters were significantly decreased in comparison with control values: volume density of follicular epithelium, as well as its height, index of activation rate and volume density of follicles (by 28%, $p < 0.01$, 10%, $p < 0.05$, 43%, $p < 0.01$ and 11% $p > 0.05$, respectively) (Figs. 3a-d). At the same time, volume densities of colloid and interstitium were increased by 26% ($p < 0.05$) and 18% ($p > 0.05$), respectively (Fig. 3a).

Peripheral Thyroid Zone. Peripheral thyroid zone consists of large follicles with dense, even cracked colloid in both control and Ca-treated rat females. Ca treatment slightly influenced this zone, with no significant changes either of structural or morphometric parameters comparing to the controls. However, these changes, although small and insignificant resembled those in the central zone of the gland, i.e. volume density of follicular epithelium, its height and index of



Figure 1. The thyroid gland of control middle-aged rat female. Follicles are composed of highly prismatic epithelium and a small portion of colloid (HE, 778×)




Figure 2. The thyroid gland of Ca-treated middle-aged rat female. Follicles are distended with colloid and lined by flattened epithelium. Macrofollicle with dense colloid in the central zone is noticeable (HE, 778×)

activation rate were decreased by 3%, 5% and 9% respectively, while volume density of colloid was increased by 5%. (Figs. 4a-d).

Total Thyroid Gland Tissue. Total (central plus peripheral) thyroid gland tissue values are reported as average grade sum value for central and peripheral zones. These results are important for the understanding of how did the whole gland respond to Ca treatment. Volume density of follicular epithelium and height of both follicles and the epithelium were decreased by 18% ($p < 0.025$), 6% ($p > 0.05$) and 8% ($p < 0.05$), respectively (Figs. 5a-c), while volume densities of colloid and interstitial tissue were increased by 6% ($p > 0.05$) and 14% ($p > 0.05$), respectively (Fig. 5a). A significant decrease of Vve and increase of Vvc resulted in a significant decrease of activation rate index by 34% ($p < 0.01$; Fig. 5d).

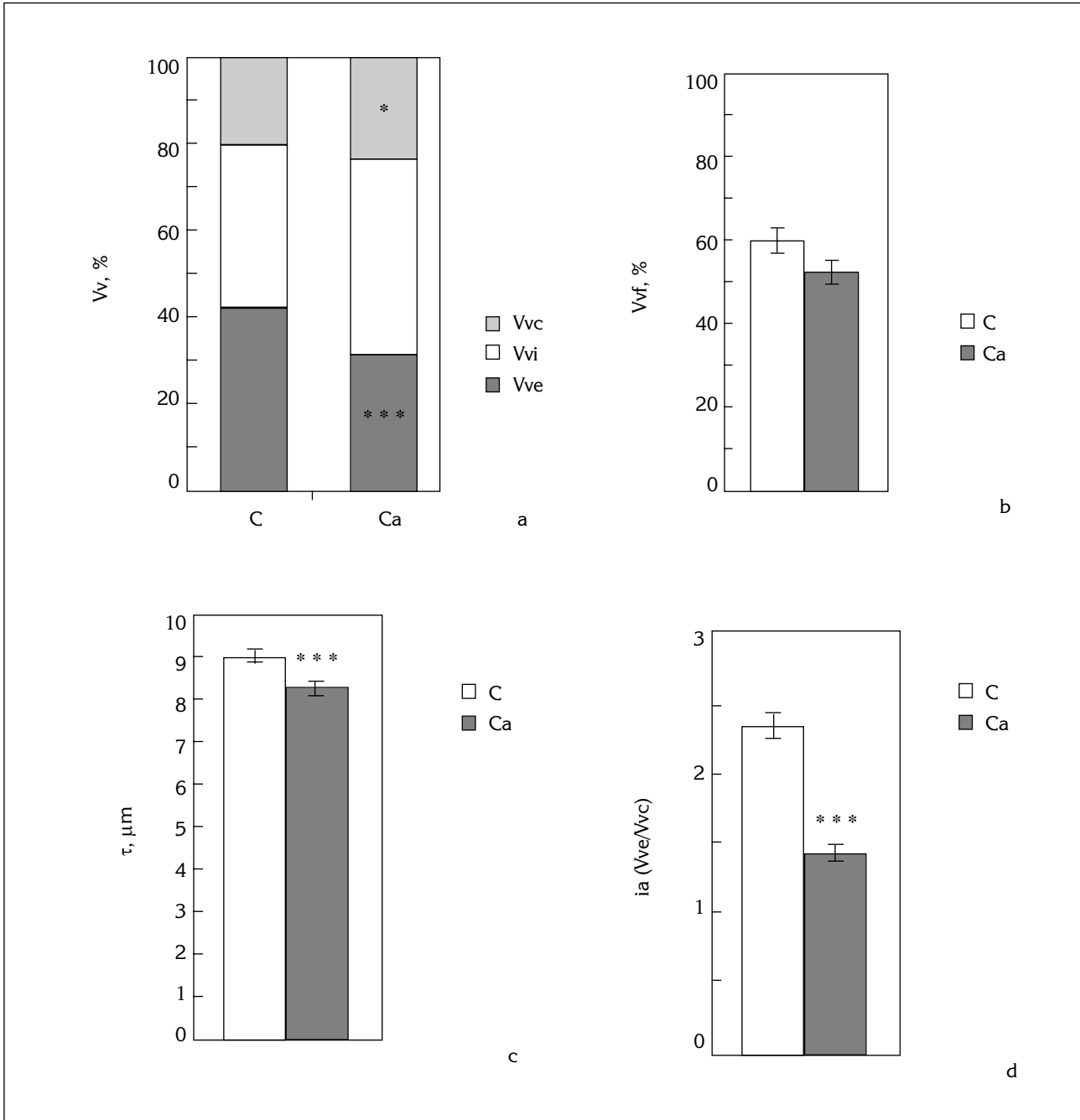


Figure 3. Morphometric parameters of central thyroid zone: volume densities of follicular cells (Vve), interstitium (Vvi), colloid (Vvc) (a), follicles (Vvf) (b), as well as the height of follicular cells (τ) (c) and index of activation rate (ia) (d) of control (C) and Ca-treated rats (Ca); The results are the means \pm SEM. *** $p < 0.001$; * $p < 0.05$.

Discussion

The thyroid gland is composed of numerous follicles of different size. Each follicle has the same basic structure with a single layer of cells surrounding a lumen, which contains colloid (16). Many authors (13 15, 17 19) suggested a correlation between the structure and metabolic function of thyroid follicles, *i.e.* the turnover of thyroglobulin molecules within the

lumen depends on the position and diameter of follicles. The thyroid contains at least two pools of organic iodine, which turn over at different rates: one is a larger pool of older hormone (large follicles in the periphery of the gland) and the other one is smaller (central follicles) and turns over more rapidly, thus providing 90% of the thyroid hormone secretion (»last come first served conceptá) (14). According to this interfollicular heterogeneity, we focused our attention

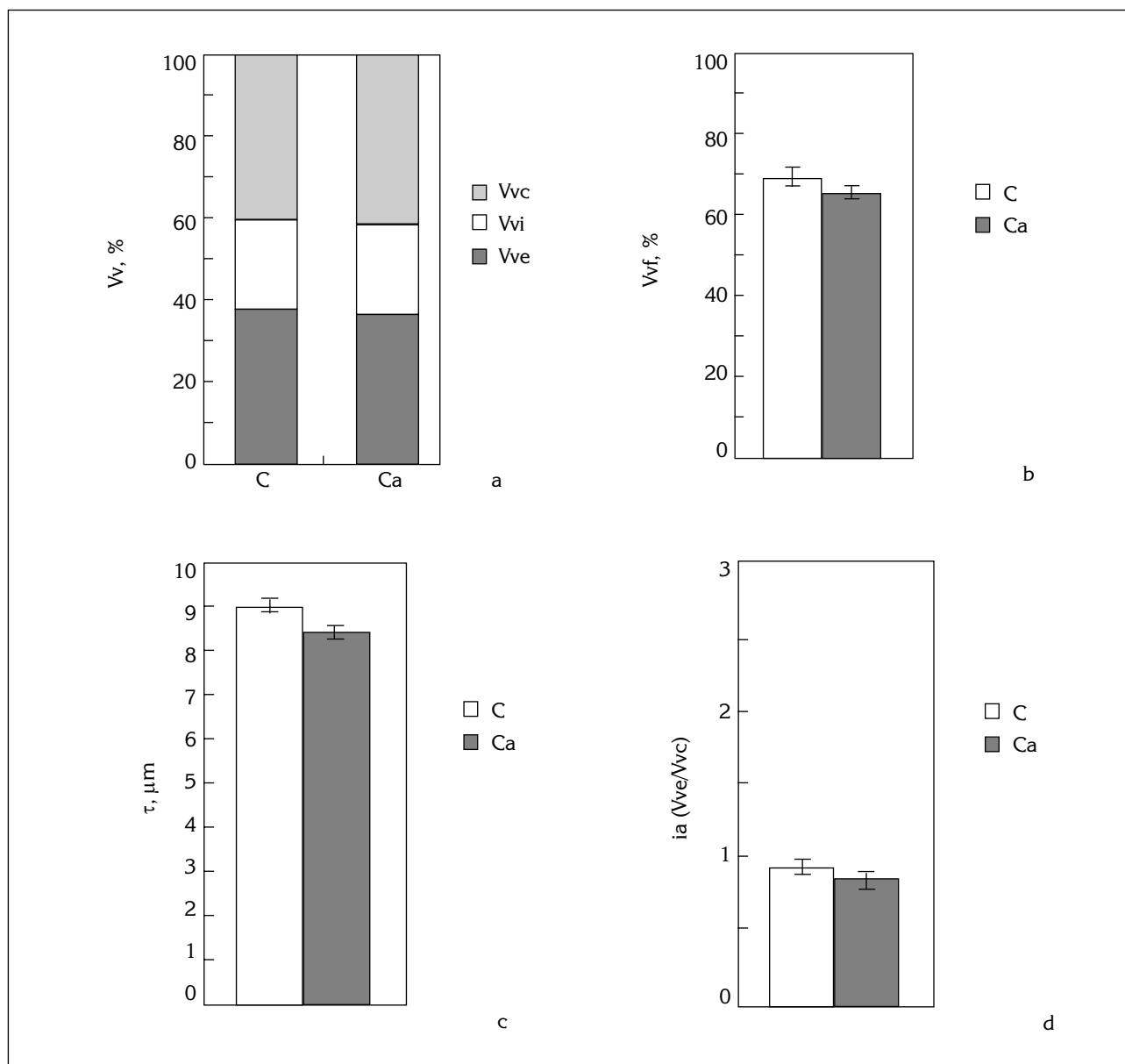


Figure 4. Morphometric parameters of peripheral thyroid zone: For the details see caption to Fig. 3; The results are the means \pm SEM.

on separate analyses of central and peripheral thyroid zone. Our results demonstrated that Ca supplementation treatment affects the central follicles to a much greater extent than the peripheral ones. Microfollicles had flattened light epithelium and enlarged follicles with denser colloid were also noticeable in this area, as compared to the controls. Morphometric parameters volume density of follicular epithelium, its height and index of activation rate, were significantly decreased in comparison with the controls. At the same time, volume density of colloid was significantly increased in relation to the value found in control animals. Peripheral thyroid gland zone responded to the treatment in the same manner as central follicles, but the res-

ponse was relatively small and insignificant. This finding is of importance, since peripheral macrofollicles are mainly considered as the depots of thyroid hormones that do not take part in thyroglobulin turnover.

The results of the present study indicate that Ca acts inhibitory on thyroid follicular cells. This effect might be due to the influence of implemented Ca treatment on three different regulation sites of thyroid function, which do not exclude each other. The first one is a direct influence of Ca on thyroid follicular cells. Calcium is a universal second messenger involved in the regulation of numerous cell activities. Montiel et al. (20) suggested that Ca entry into FTRL-

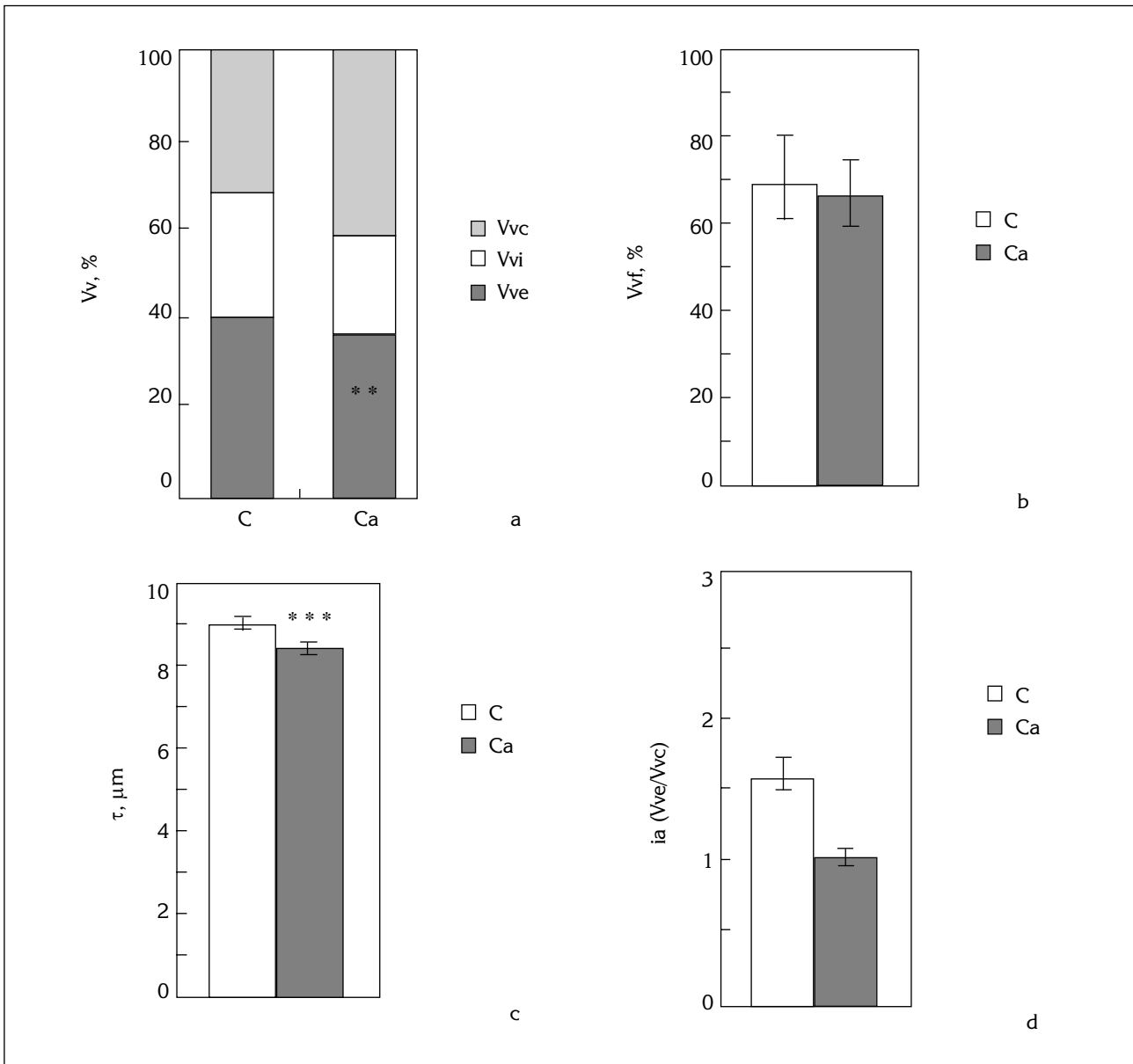


Figure 5. Morphometric parameters of total (central plus peripheral) thyroid gland tissue: For the details see caption to Fig. 3; The results are the means \pm SEM. **p < 0.025; ***p < 0.001.

5 follicular cells culture occurs through the L-type voltage-dependent Ca channels and the capacitative pathway mechanism. Gaberscek et al. (2) showed that extracellular Ca even at high concentrations did not affect the FTRL-5 cells morphology, but given together with TSH, it acted by diminishing thyrotropin stimulatory effect. Vanvooren et al. (5) reported three different isoforms of adenyl cyclase, the enzyme crucial in TSH activation of cAMP cascade in follicular cells in human and dog thyroids. According to these authors one of these three isoforms, adenyl cyclase VI, is negatively modulated by Ca. Therefore Ca treatment may directly affect thyroid follicular cells.

The second site is related to the influence of calcium treatment on pituitary-thyroid axis. It has been suggested by Gillet et al. (7) that chronic and acute hypercalcemia in humans changes the set point of pituitary-thyroid feedback, leading to a decreasing TSH secretion while serum circulating concentrations of T₄ and T₃ were normal. Bergenfelz et al. (8) showed that even small and slow changes of calcium within the physiological range reduced the serum levels of thyrotropin. Consistent with these findings in men, Sekulić et al. (9) reported that calcium supplementation of middle-aged rat females decreased all examined morphometric parameters of pituitary TSH cells and this was interpreted as a sign of their reduced syn-

thetic capacity. Thus, Ca treatment might affect the thyroid gland indirectly, as well, through its inhibitory influence on TSH cells.

The third regulation site includes paracrine effect of neuropeptides secreted by the C cells on thyroid follicular cells. These cells are situated adjacent to thyroid follicular cells and in response to increased external Ca they release calcitonin and serotonin (21). The data of several authors (2-4) support the hypothesis that serotonin secreted by the C cells serves as a paracrine stimulating factor in the regulation of thyroid follicular cells activity. Sekulić et al. (21) reported that Ca supplementation treatment of middle-aged female rats did not significantly change the examined morphometric parameters of C cells, but the structural features of these cells pointed out to their increased

activity. These authors suggested that the peptides released from C cells might be involved via paracrine pathway in follicular cell activity, but rather by inhibition than by stimulation. It can be assumed that C cells might affect the follicular cells, either by stimulation or inhibition.

The data obtained in the present study indicate the inhibitory effect of chronic calcium treatment on thyroid follicular cells structure. However, further studies are necessary for a precise determination of this effect. Since the calcium supplementation therapy is widely applied in the prevention and therapy of osteoporosis, these results are of both fundamental and practical significance.

Acknowledgement This work was supported by the Ministry for Science and Technology of Serbia.

EFEKAT KALCIJUMA NA STRUKTURNE I MORFOMETRIJSKE KARAKTERISTIKE ŠTITASTE ŽLEZDE ACIKLIČNIH ŽENKI PACOVA

Branka Šošić-Jurjević, Branko Filipović, Nataša Nestorović, Mirjana Louren, Milka Sekulić

Institut za biološka istraživanja »Siniša Stankovićá, Beograd, Jugoslavija

Kratak sadržaj: Ispitivan je efekat kalcijum glukohেptonata na strukturne i morfometrijske karakteristike štitaste žlezde acikličnih 14 meseci starih ženki pacova. Serijski preseki štitastih žlezda korišćeni su za stereološku analizu centralnih i perifernih delova žlezde. Sledeći morfometrijski parametri su bili statistički značajno smanjeni u odnosu na kontrolne vrednosti: volumenska gustina epitela, njegova debljina i indeks aktivacije (za 18%, $p < 0,025$, 8%, $p < 0,05$ i 34%, $p < 0,01$, respektivno). Volumenska gustina koloida bila je povećana za 10%, a intersticijuma za 14% ($p > 0,05$). Dobijeni rezultati jasno ukazuju da hronično tretiranje acikličnih ženki pacova terapijskim dozama Ca deluje inhibitorno na folikularne ćelije štitaste žlezde.

Cljučne reči: aciklične ženke pacova, štitasta žlezda, folikularne ćelije, kalcijum, morfometrija.

References

- Elders P, Netelenbos J, Lips P, Ginkel FC van, Khoe E, Leeuwenkamp O, et al. Calcium supplementation reduces vertebral bone loss in perimenopausal women: A controlled trial in 248 women between 46 and 55 years of age. *J Clin Endocrinol Metab* 1991; 73: 533-40.
- Kalisnik M, Vraspir-Porenta O, Kham-Lindtner T, Logonder-Mlinsek M, Pajer Z, Štiblar-Martinčić D, et al. The interdependence of the follicular, parafollicular, and mast cells in the mammalian thyroid gland: A review and a synthesis. *Amer J Anat* 1988; 183:148-57.
- Tamir H, Hsiung S, Yu P, Liu K, Adlersberg M, Nunez E, Gershon M. Serotonergic signalling between thyroid cells: protein kinase C and 5-HT₂ receptors in the secretion and action of serotonin. *Synapse* 1992; 12: 155-68.
- Gaberscek S, Štiblar-Martinčić D, Kalisnik M. The influence of serotonin on follicular cells FRTL-5 in vitro. *Folia Biol (Praha)* 1997; 43: 105-8.
- Gaberscek S, Štiblar-Martinčić D, Kalisnik M. The influence of calcium on thyroid follicular cells FRTL-5 in vitro. *Folia Biol (Praha)* 1998; 44: 49-52.
- Vanvooren V, Allgeier A, Cosson E, Van Sande J, Defer N, Pirlot M, Hanoune J. Expression of multiple adenyl cyclase isoforms in human and dog thyroid. *Mol Cell Endocrinol* 2000; 170: 185-96.
- Gillet C, Corvilain J, Matte-Jiriart J, Willems D, Bergmann P. Effect of acute hypercalcemia on thyrotropin (TSH) and triiodothyronine responses to TSH-releasing hormone in man. *J Clin Endocrinol Metab* 1990; 71: 516-9.
- Bergenfelz A, Ahren B. Serum levels of thyrotropin are

- decreased by oral calcium in healthy subjects but not in patients with primary hyperparathyroidism. *Hormone Res* 1994; 42: 273-7.
9. Sekulić M, Lovren M, Milošević V. Immunoreactive TSH cells in the pituitary of female middle-aged rats after treatment with estradiol or calcium. *Acta histochem* 1998; 100: 185-91.
 10. Šošić-Jurjević B, Filipović B, Nestorović N, Negić N, Lovren M, Sekulić M. Morphometry of thyroid gland tissue in middle-aged female rats after chronic Ca treatment. 26th Congr of YAA with International Participation, Herceg Novi, Yugoslavia 2001: 76.
 11. Weibel E. *Stereological Methods. Practical Methods for Biological Morphometry*. Academic Press, London 1979; 1: 415.
 12. Bogataj M, Kališnik M, Poredoš P. A simplified indirect method of the average shell thickness of the hollow spheres from samples in sections. *Folia Anat Jugosl* 1977; 6: 45-9.
 13. Loewenstein J, Wollman S. Kinetics of isotopic equilibration of iodine in individual rat thyroid follicles. *Endocrinology* 1973; 92: 894-911.
 14. Penel C, Rognoni JB, Bastiani P. Thyroid morphological and functional heterogeneity: impact on iodine secretion. *Gen Physiol Biophys* 1985; 4: 55-68.
 15. Penel C, Bastiani P, Rognoni JB. Correlation between thyroid-follicle fusion and structural modifications of the epithelial cells. *Cell Tissue Res* 1982; 225: 143-53.
 16. Wollman S. *Structure of the thyroid gland. The Thyroid Gland* (Ed. M. De Visscher), Raven Press, London 1980; 1: 19.
 17. Nadler N, Leblond C, Bogoroch R. The rate of iodine metabolism by the thyroid follicle as function of its size. *Endocrinology* 1954; 54: 154-72.
 18. Miloni E, Studer H. Functional and morphological particularities of the autonomous follicles in human goiters. *J Mol Med* 1980; 4: 7-20.
 19. Bazin JP, Fragu P, Di Paola R, Tubiana M. Early kinetics of thyroid trap in normal human patients and in thyroid diseases. *Eur J Nucl Med* 1981; 6: 317-26.
 20. Montiel M, Pavia J, Marsigante S, Jimenez E. Activation of muscarinic acetylcholine receptors induces Ca^{2+} mobilization in FRT cells. *Cell Signal* 2001; 13: 207-12.
 21. McGehee D, Aldersberg M, Liu K, Hsuing S, Heath M, Tamir H. Mechanism of extracellular Ca^{2+} receptor-stimulated hormone release from sheep thyroid parafollicular cells. *J Physiol* 1997; 502 (Pt 1): 31-44.
 22. Sekulić M, Lovren M, Milošević V, Mičić M, Balint-Perić L. Thyroid C cells of middle-aged rats treated with estradiol or calcium. *Histochem Cell Biol* 1998; 109: 257-62.

Received: November 19, 2001

Accepted: January 21, 2002